

## **AHL LabNote** Number 58

updated May 2020

### **Infectious laryngotracheitis (ILT) Infections in small poultry flocks**

*Marina Brash, Csaba Varga, Al Dam, Lloyd Weber*

#### **What is ILT?**

Infectious laryngotracheitis (ILT) is a contagious viral respiratory disease, primarily of chickens and gamebirds, that can cause elevated morbidity and mortality. Based on the results of the Disease Surveillance in Ontario Non-commercial Poultry Flocks study conducted from 2015-2017, small non-commercial chicken flocks are more likely to be infected with the ILT virus than commercial chicken flocks. ILT related morbidity and mortality was diagnosed in 9 % of the chicken submissions. An additional 7.5 % of the submissions were shown to be latent carriers (not exhibiting any clinical signs) of the ILT virus. These birds could shed the virus through respiratory and ocular secretions, putting the rest of the resident flock at risk of developing clinical disease. If these birds were introduced into a naïve flock, an outbreak of ILT would probably occur.

#### **What causes ILT?**

ILT virus is a member of the Herpesviridae, and *Gallid herpesvirus 1* species. Transmission of the virus can be through direct and indirect routes. The virus can survive in expelled ocular, nasal and tracheal discharge in the environment for several days to months at room temperature. The virus can survive for even longer periods of time if kept cold or frozen (in buried infected carcasses). ILT is an enveloped virus and is sensitive to heat, direct sunlight and common disinfectants. However, disinfectants are less effective in the presence of organic matter such as fecal material.

#### **How can ILT virus enter into my flock?**

ILTV can be introduced into your flock in several ways, including infected live birds and numerous vectors and fomites including:

- other small flock owners
- companion animals, wild birds
- darkling beetles
- contaminated coveralls, boots and equipment
- improper dead bird disposal
- improper handling of infected manure
- wind

The ILT virus can persist for extended periods of time in birds that have recovered from the disease or have been previously vaccinated with either the live attenuated ILTV vaccine of chicken embryo origin (CEO) or tissue culture origin (TCO). Both the field and CEO vaccine strains of the virus are more likely to be re-activated during periods

of stress allowing the virus to spread to susceptible, unvaccinated birds. The incubation period is 4-7 days so it is possible to introduce subclinically infected chickens into a naïve flock.

To prevent infections, it is important that all the chickens in a flock are annually vaccinated and good biosecurity protocols are in place. For more information about disease vectors and proper biosecurity protocols for small flocks, please visit the Ontario Ministry of Agriculture and Food and Rural Affairs (OMAFRA) website at: <http://www.omafra.gov.on.ca/english/livestock/poultry/health.html>

### **How is ILT diagnosed?**

Typically, chickens older than 3- 4 weeks-of-age are most susceptible to ILT virus. In the acute phase of disease, the birds may just be found dead or have:

- swollen eyelids and/or infraorbital sinuses
- sneezing and bubbly ocular and nasal discharge

Since the birds are in respiratory distress, they may have:

- extended heads and necks to aid breathing
- gasping or coughing up blood tinged mucus or exudate
- increased mortality in the flock

At postmortem, birds may have:

- ocular and nasal discharge
- swelling of the eyelids and reddening of the conjunctiva
- plaques of pale fibrinous exudate on the oropharyngeal and esophageal mucosa (Fig 1)
- laryngeal opening plugged with fibrinous exudate (Fig 1)
- reddened tracheal mucosa with luminal blood or fibrinous exudate (Fig 2)

Diagnosis of ILT can only be confirmed by identifying the herpesvirus through laboratory testing such as postmortem, histology and virology. This is important because other viral and bacterial respiratory pathogens can cause similar clinical signs.

### **I think my birds are sick with ILT, what happens next?**

1. If ILT is suspected in the flock, immediately self-quarantine the premises and contact your veterinarian. A postmortem and additional laboratory testing are required to confirm the diagnosis.
2. ILT is an immediately notifiable disease / hazard. Thus, if ILT is diagnosed in a poultry flock in Ontario, the Canadian Food Inspection Agency (CFIA) and the Ontario Ministry of Agriculture, Food and Rural Affairs (OMAFRA) are notified. An OMAFRA veterinarian will follow up with the flock veterinarian to ensure that the flock is being properly managed and heightened biosecurity has been implemented.
3. As there is no treatment for ILT, sick non-recovering chickens should be euthanized. For more information on euthanasia, please visit the Poultry Industry Council website at: <http://www.poultryindustrycouncil.ca/resources/euthanasia-resources-training-materials/>. Also, check with your municipality if there are any other restrictions, (i.e. birds in an urban setting). For more information on proper disposal of deadstock, please visit the OMAFRA website at: <http://www.omafra.gov.on.ca/english/livestock/deadstock/index.html>. The environment and equipment where the birds have been housed will contain large amounts of virus particles. Thorough cleaning to remove organic matter followed by disinfection using commercially available virucidal disinfectants is required.
4. Heating of the barn to 38°C (100°F) for a minimum of 3 days will allow the manure to be heat-treated to reduce the viral load (this may not be an option for small flock owners). Composting of your infected manure can also reduce the viral load.

5. There is increased risk of introducing ILT virus into flocks when adding new birds of unknown health status or reintroducing birds returning from shows. It is important to quarantine birds by physically separating them from the rest of the flock for 3-4 weeks. The quarantined birds should be kept in a separate room with their own ventilation, feed, and water systems, and dedicated footwear and clothing should be worn. They should also be the last group of birds visited during daily chores.
6. Birds can be vaccinated for ILT. For day-old chicks purchased from commercial hatcheries, live recombinant vector vaccination (INNOVAX®-ILT) is an option. Vaccination of birds 4 weeks and older can be done on farm using eye drop applied live attenuated virus (TCO) vaccine (LT-IVAX®) following manufacturer's instructions (Fig 3). Annual revaccination is recommended.
7. Poultry vaccines are dispensed in large multi-dose vials meant for the commercial poultry industry. The impact of ILT in your flock can be devastating compared to the cost of throwing out unused vaccine. The unused vaccine will need to be properly discarded according to manufacturer's instructions.

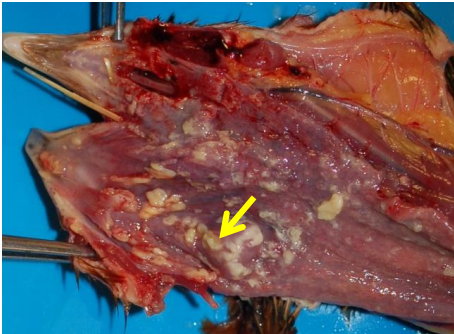


Fig 1: ILT: The laryngeal opening is occluded by fibrinous exudate (arrow). There are plaques of fibrinous exudate on the oropharyngeal and esophageal mucosa. This chicken was in extreme respiratory distress due to a plugged opening to the airway.

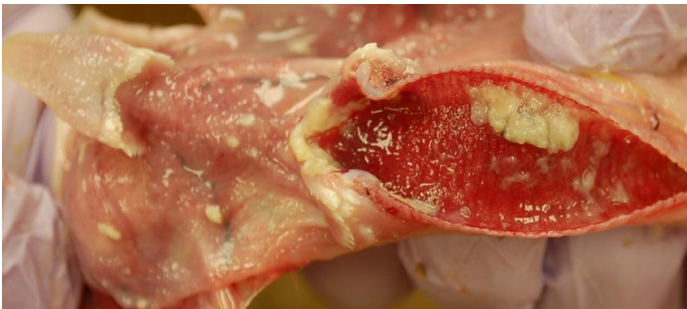

Fig 2: ILT. There is fibrinous exudate in the laryngeal opening and also in the tracheal lumen. The tracheal mucosa is hyperemic. A few small plaques of fibrinous exudate are also on the oral and esophageal mucosa.



Fig 3: Eye drop application of ILT vaccine.